

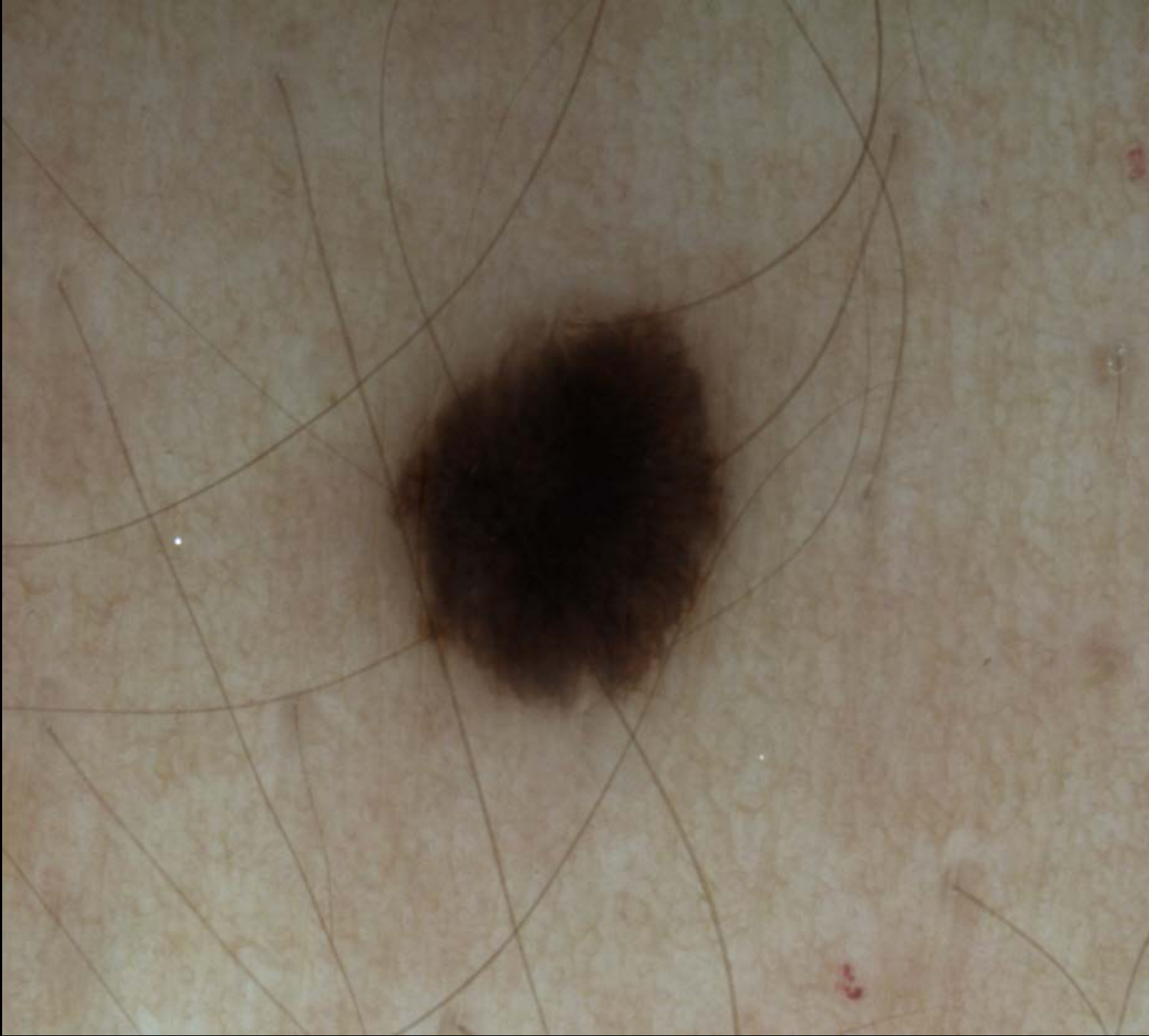# CASE OF THE MONTH 2 (september 2018)

Dr. Segurado, Dra. Encabo


Cutaneous Oncology and Non-Invasive Diagnosis Unit (S.G.), Group of Dermatology  
P.J., Madrid, Spain.

# Clinical History

- 28 year old male patient
- No relevant personal or familiar dermatological history
- Pigmented lesion in his right flank which had grown in the last year

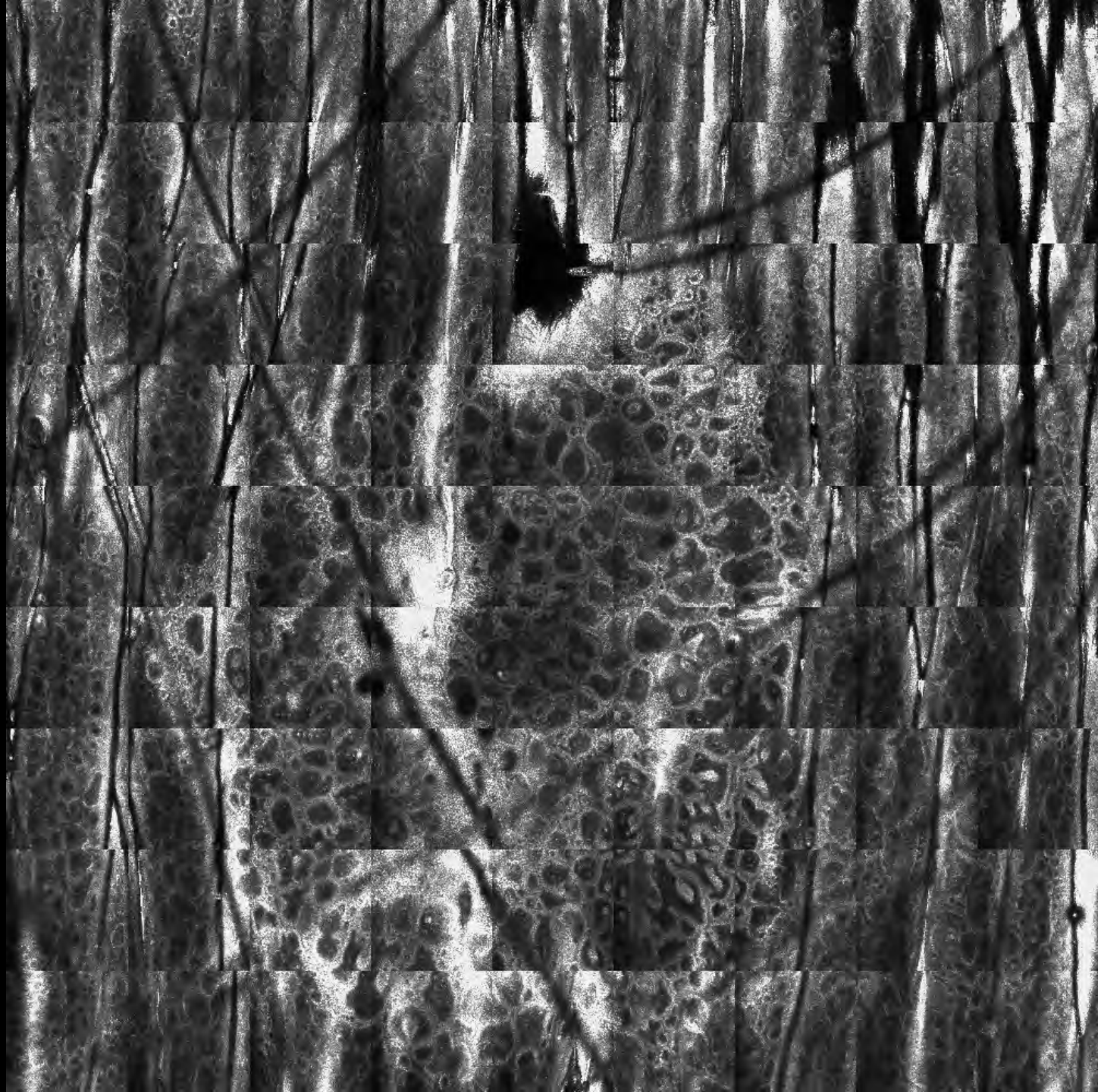

**Vivablock from the  
epidermis-basal layer**



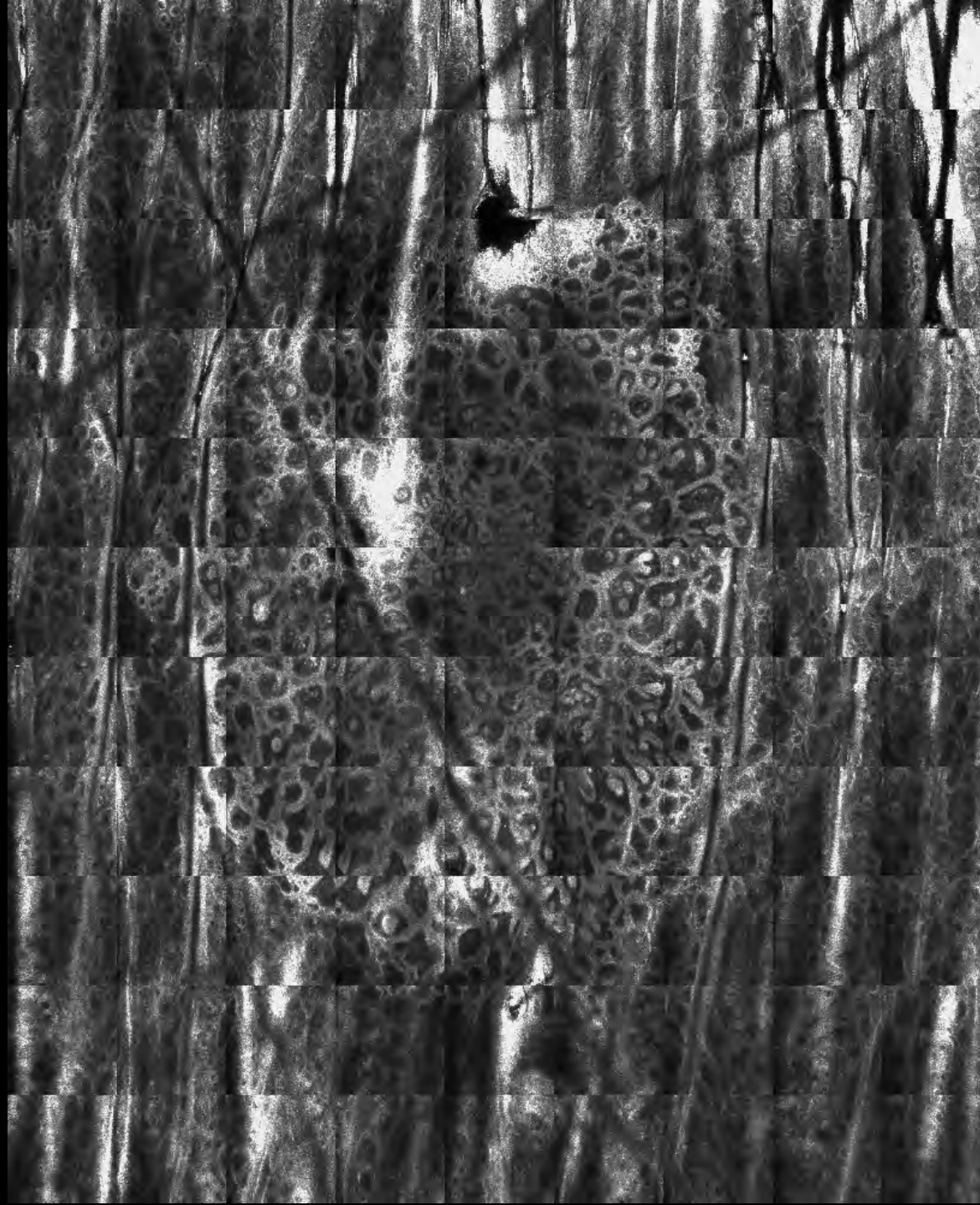

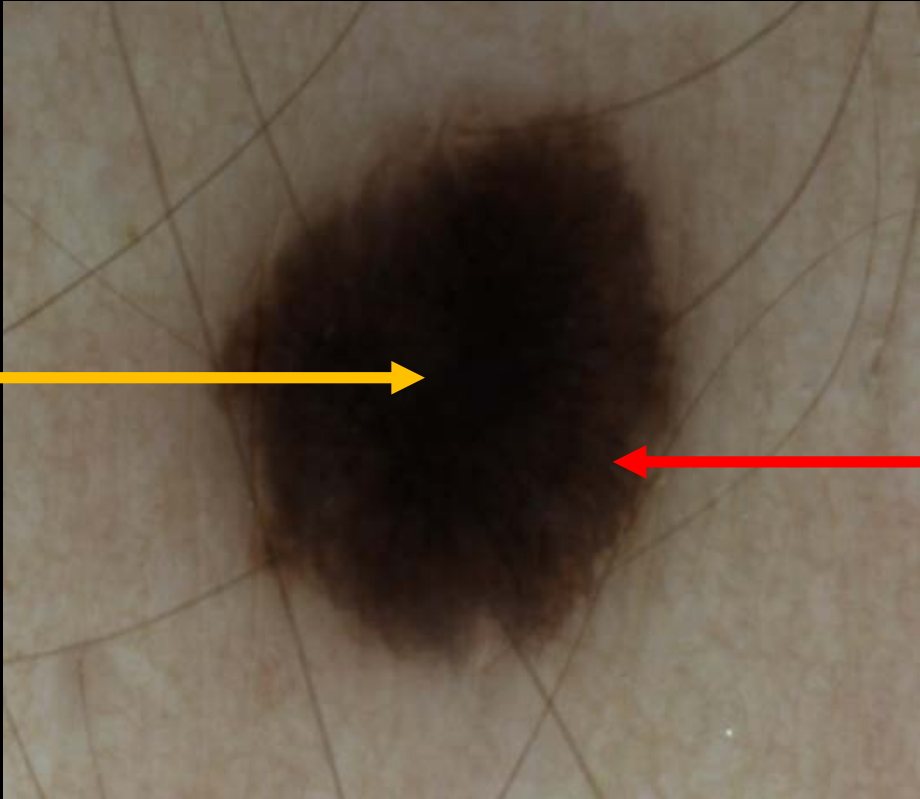
**Vivablock (VB) from  
the dermo-epidermal  
layer**





**Vivablock from the  
dermal layer**

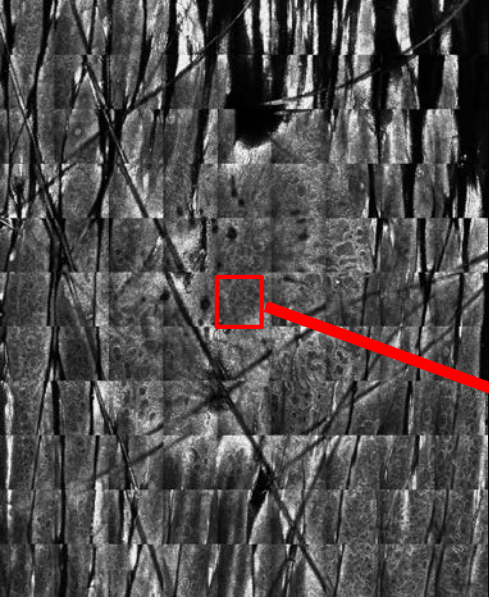




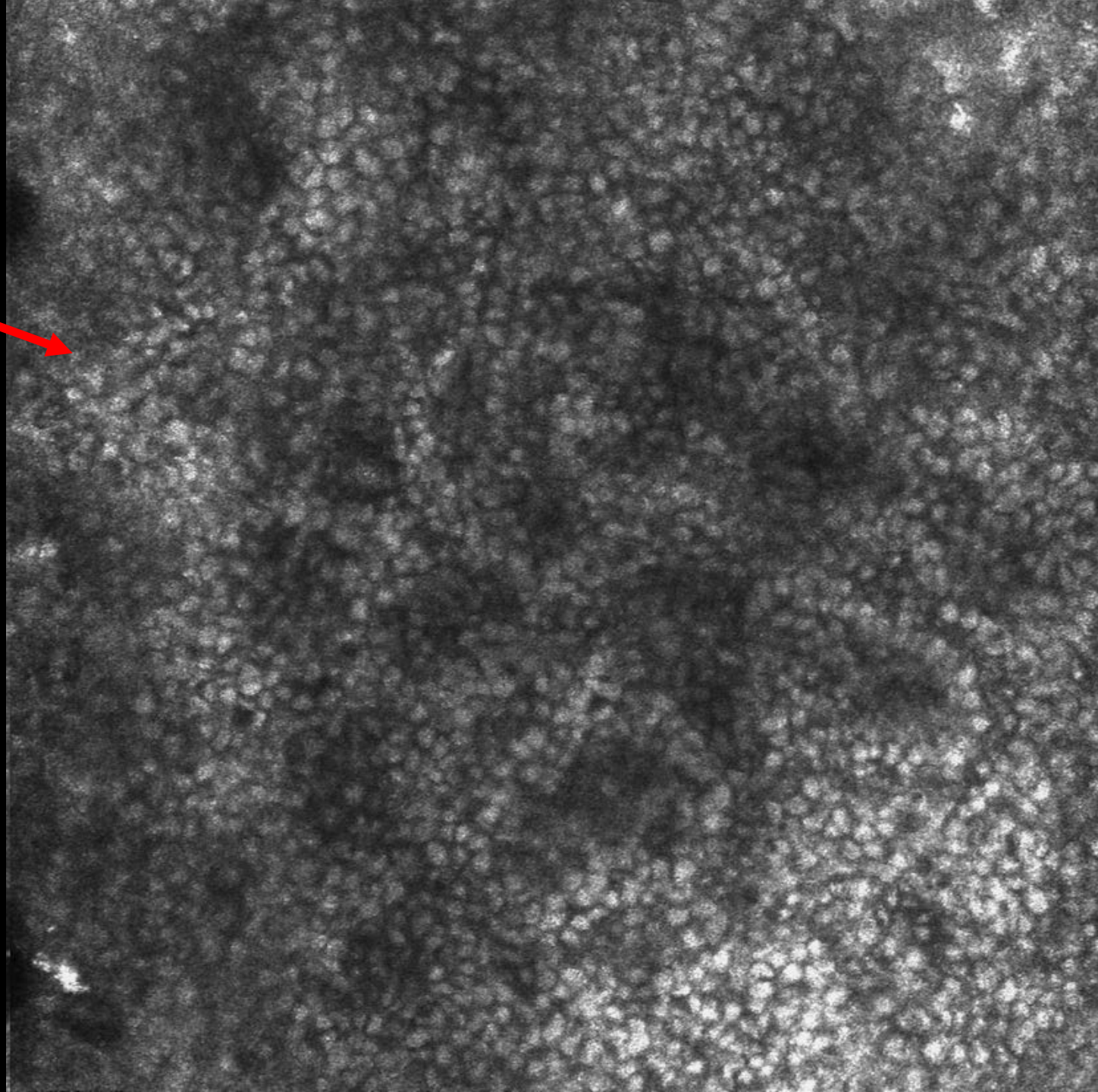
**Central pigmented blotch**

**Broadened network**





**Zoom (0,5x0,5mm) of  
the vivablock of the  
basal layer:  
- Typical cobblestone  
pattern**

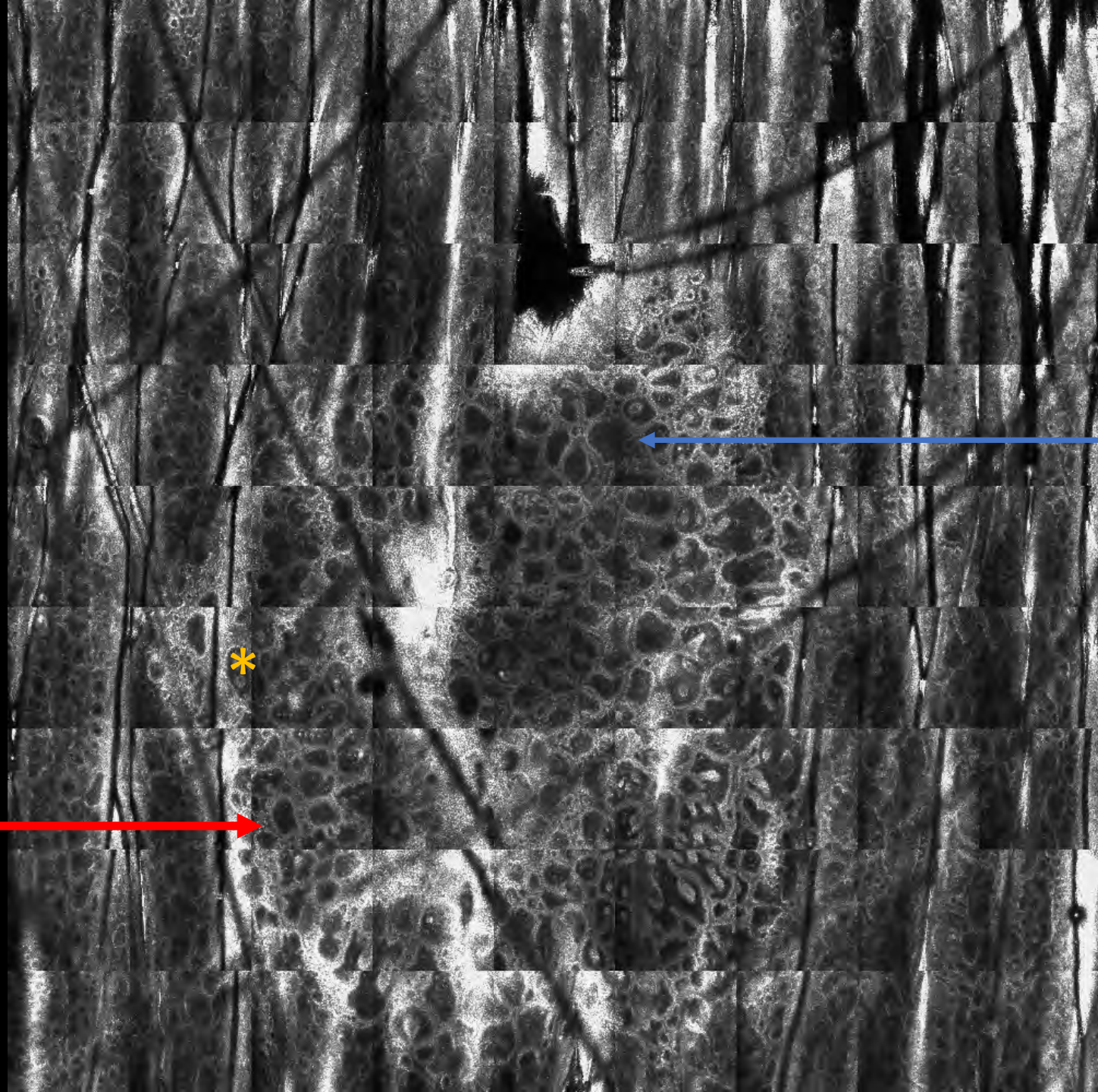




**VB- dermo-epidermal layer**

**\*** : melanocytic clods in the dermal papilla

**Focal meshwork pattern (junctional thickenings)**



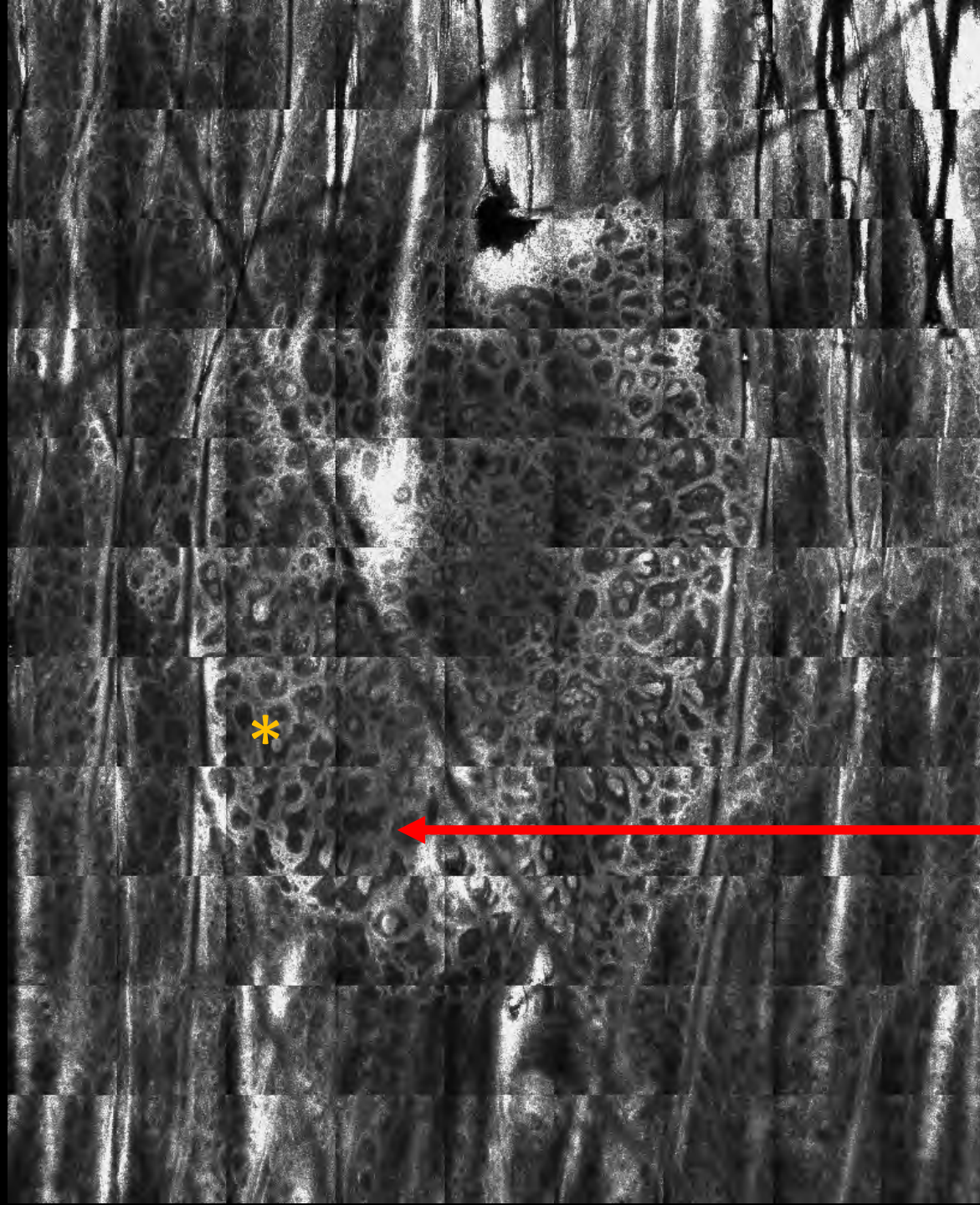
**Ringed edged-papilla**

\*



**Vivablock from the  
dermal layer**

**\*** : melanocytic  
clods in the dermal  
papilla



**Meshwork  
pattern  
(junctional  
thickenings)**

# CONFOCAL DIAGNOSIS



## COMPOUND MELANOCYTIC NEVUS



- Typical cobblestone pattern
- Ringed edged-papilla
- Melanocytic clods inside the dermal papilla
- Absence of pagetoid cells